

Allergic bronchopulmonary aspergillosis simulating as lung mass

Dr. Vipul Kumar¹, Dr. Nitika Garg², Dr. Jyoti Yadav³

¹⁻³ Department of Respiratory Medicine, Pt BD, Sharma University of Health Sciences, Rohtak, Haryana, India

DOI: <https://doi.org/10.33545/26648504.2019.v1.i1a.3>

Abstract

Allergic bronchopulmonary aspergillosis (ABPA) is a commonly diagnosed entity in patients with a long standing history of asthma. Patients with ABPA can have diverse radiological manifestations. Very rare cases of ABPA, presenting as lung mass have been reported. We hereby report a case of ABPA in whom a large symptomatic lung mass was the presenting manifestation leading to consideration of lung cancer as a differential diagnosis. The establishment of ABPA as the underlying cause lead to conservative medical treatment, which was followed by complete resolution of the mass like opacity.

Keywords: Allergic bronchopulmonary aspergillosis, aspergillus, hypersensitivity, eosinophilia

1. Introduction

Allergic bronchopulmonary aspergillosis (ABPA) is a disorder caused by hypersensitivity to the fungus, *Aspergillus fumigatus*, which is the main underlying pathogenic mechanism. Patients with ABPA may present with recurrent asthma exacerbations, expectoration of dark brown mucus plugs, hemoptysis, or systemic symptoms such as fever, anorexia, malaise, or weight loss. The estimated prevalence of ABPA is about 1% to 2% in patients with bronchial asthma and 2% to 15% in patients with cystic fibrosis [1]. The most commonly used criteria for diagnosis of ABPA are the Rosenberg-Patterson criteria [2-4] and include 8 major and 3 minor criteria. The major criteria can be remembered by the mnemonic ARTEPICS (4). These include asthma, roentgenographic evidence of fleeting pulmonary opacities, skin test positive for aspergillus (Type I reaction), eosinophilia, precipitating antibodies (IgG) against aspergillus in the serum, elevated serum IgE levels (>1,000 IU/mL), central bronchiectasis and elevated serum *Aspergillus fumigatus* - specific IgG and IgE. The minor criteria include presence of *Aspergillus* in sputum, expectoration of brownish black mucus plugs and delayed skin reaction to *Aspergillus* antigen (type III reaction).

If 6 out of the 8 major criteria are met, the diagnosis of ABPA is almost certain. Based on radiological findings, the disease is classified as ABPA-S (serologic) or ABPA-CB (central bronchiectasis) respectively depending on the absence or presence of bronchiectasis [4]. The common radiographic findings include lobar or segmental collapse, focal areas of consolidation, finger in glove opacities representing mucoid impaction and bronchiectasis [4]. Pulmonary masses are very uncommonly reported. We hereby report a case of ABPA presenting with a symptomatic lung mass, which was successfully managed with conservative medical treatment.

2. Case Report

A 40-year-old non-smoker female was referred to our chest clinic with a 2-month history of worsening breathlessness,

vague right upper chest pain, and streaky hemoptysis. She had a history of anorexia and weight loss of 4 kg, without fever or cough. She had not any history of chronic illness like asthma, hypertension etc. She also had a history of surgery for sinonasal polyposis 3 year back. On general physical examination, the patient had respiratory rate of 16/min without any use of accessory muscles of respiration. Breath sounds were reduced in intensity over the right infra-clavicular region, and no wheeze. A chest radiograph showed a right-upper-zone mass, which was confirmed on computed tomography (CT) (Fig. 1). Computed tomographic (CT) examination of the thorax was performed on which the mediastinal window sections demonstrated a large (73 mm × 79 mm) centrally situated mass in the right upper lobe (Fig. 2A). Lung window sections demonstrated focal areas of bronchiectasis adjacent to the mass (Fig. 2B).

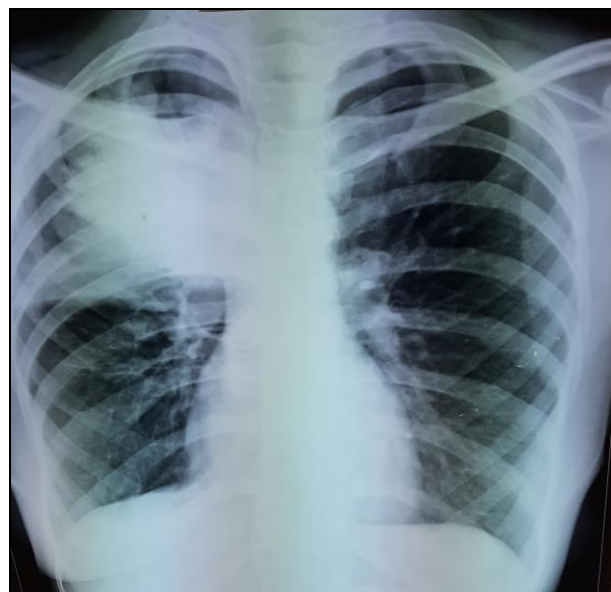


Fig 1: Postero-anterior chest radiograph demonstrating mass like rounded opacity in the right upper zone.

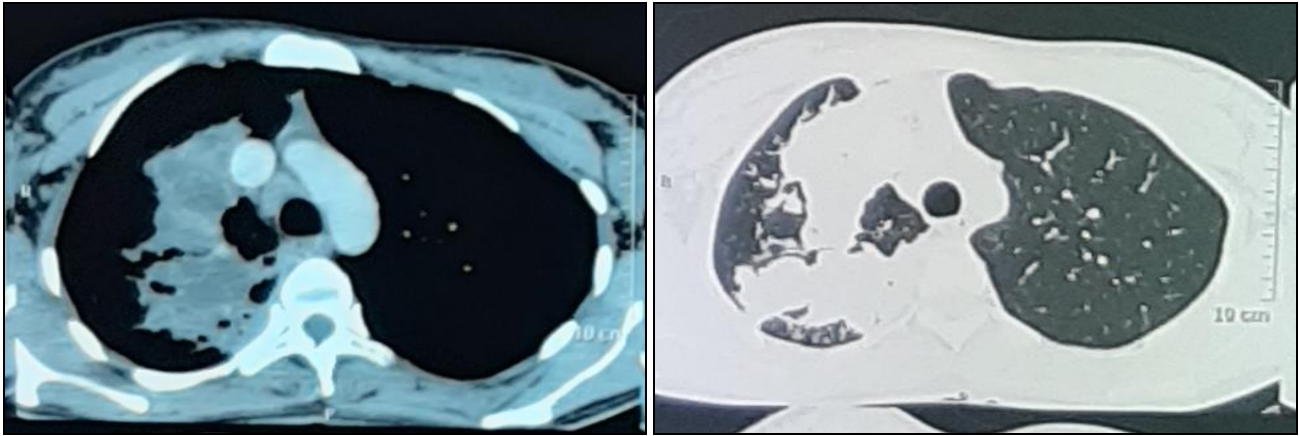


Fig 2: Contrast enhanced CT scan of the thorax (mediastinal window, A) showing a centrally situated mass in the right upper lobe. Focal bronchiectasis is seen adjacent to the mass (lung window, B).

CT examination of paranasal sinus showed sinonasal polyposis involving bilateral ethmoid and sphenoid sinus with hypertrophy of right inferior nasal turbinate (Fig. 3A). Flexible bronchoscopic examination revealed normal bronchial anatomy with no endobronchial obstruction and bronchoalveolar lavage fluid (BALF) was negative for acid-fast bacilli, fungi, and malignant cells, but showed eosinophilia of 7%. In view of the presence of a large right upper lobe mass lesion, hemoptysis, chest pain and recent

worsening of symptoms, a possibility of bronchogenic carcinoma was considered and CT guided fine needle aspiration cytology (FNAC) was done. The CT guided Lung FNAC was suggestive of chronic eosinophilic pneumonia, so, in view of her cytology finding of eosinophilic pneumonia, hemoptysis, sinonasal polyposis, presence of bronchiectasis, and BAL eosinophilia, investigations were also requested for ABPA.

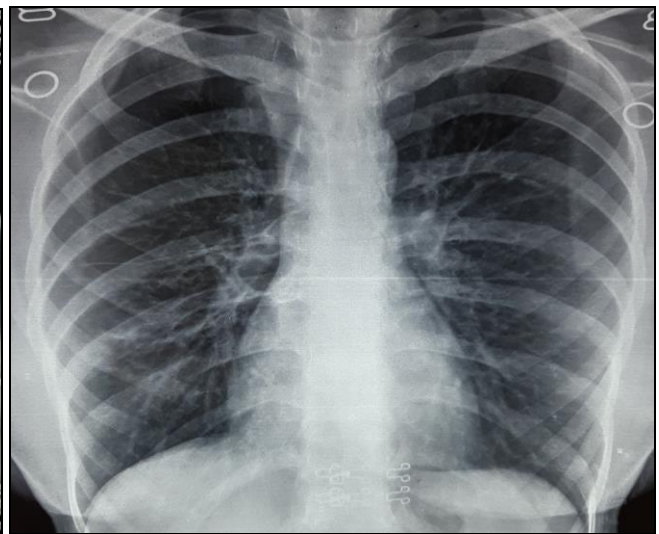
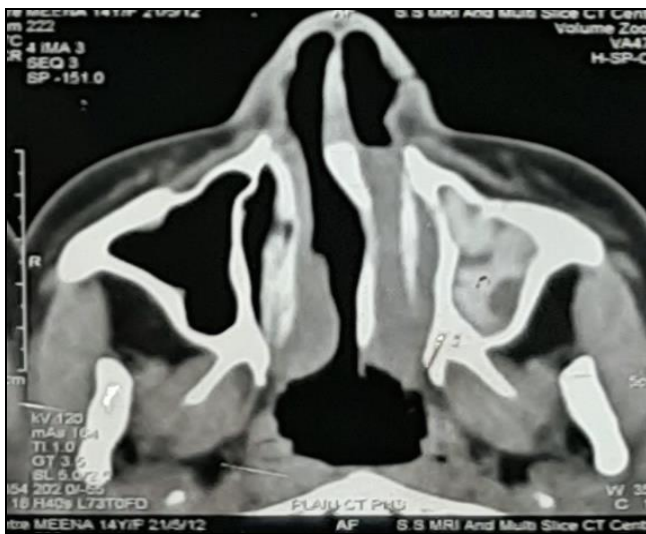

Fig 3: Contrast enhanced CT scan of the paranasal sinus (A) showed sinonasal polyposis with hypertrophy of right inferior nasal turbinate. Chest radiograph (B) obtained one month later demonstrated significant resolution of the right upper lobe mass lesion.

Serum IgE levels were found to be markedly elevated (6,404 IU/mL) and markedly elevated titres of *Aspergillus fumigatus* specific IgE (Patient's value specific IgE - 14.90 kUA/L, Normal value <0.1 kUA/L) were present. Precipitins to *A. fumigatus* were positive (Patient's value specific IgG – above 200 U/ml, Normal value <8 U/ml). Absolute eosinophil count was elevated (1464 cells/mm³). Spirometry demonstrated a mild obstructive defect and substantial bronchodilator reversibility. Serum C-ANCA was also negative to rule out vasculitis. With these considerations, a diagnosis of ABPA- CB (Allergic bronchopulmonary aspergillosis-central bronchiectasis) was made. The patient was started on treatment with Prednisolone and Itraconazole. A chest radiograph obtained one month later demonstrated significant resolution of the right upper lobe mass lesion (Fig. 3B). We started her on

prednisolone 40 mg/d, with which she had complete resolution of all her symptoms. Itraconazole was discontinued at 3 months. Prednisolone was tapered and stopped after a total course of 9 months. The serum IgE level was reduced on follow up and the patient was advised to follow up with serum IgE levels and chest-xray at six weekly intervals. She is doing well on follow-up at 1 year.

3. Discussion

Involvement of the respiratory system with *Aspergillus* can be broadly classified into three main types. These include saprophytic (*Aspergilloma*), allergic [allergic aspergillus sinusitis, allergic bronchopulmonary aspergillosis (ABPA), and hypersensitivity pneumonitis] and invasive (airway invasive aspergillosis, chronic necrotizing pulmonary aspergillosis, and invasive aspergillosis) [4].

ABPA is a complex immune hypersensitivity reaction that manifests when the bronchi become colonized by *Aspergillus*, although there are 200 species of *Aspergillus*, only a few have been reported to cause ABPA: *A. fumigatus*, *A. flavus*, and *A. Niger*. Patients with ABPA can have diverse radiological manifestations including transient migratory radiographic opacities secondary to eosinophilic pneumonia [5]. High-resolution CT characteristically shows central bronchiectasis, mucus-filled bronchi, consolidation, and centri-lobar nodules [4]. Presence of pulmonary masses is an uncommon radiological manifestation. To the best of our knowledge, 10 cases of ABPA presenting as a lung mass have been previously reported. It is important to note that ABPA can very well be diagnosed in patients without history of asthma. Out of the previously reported 10 cases of lung masses in patients with ABPA, 3 patients had no preceding history of asthma. This is particularly important because in these patients, presence of a lung mass can lead to strong consideration of lung cancer as a diagnostic possibility and lead to invasive diagnostic procedures to establish an accurate diagnosis. Sanchez-Alarcos *et al* [6], reported a 65 year old male smoker patient without any history of asthma, who underwent right upper lobectomy due to the presence of radiological appearance of a lung mass. Even though, histopathological examination of the excised tissue demonstrated bronchial dilatations and mucoid obstruction with eosinophilic inflammation, the diagnosis of ABPA was delayed for one year following surgery. These masses in ABPA are usually attributed to the bronchial plugging with mucus leading to distal accumulation of secretions [6, 7, 8, 9], presence of large non-obstructed bronchoceles (mucus-filled dilated bronchi) [7, 8] and probable inflammatory eosinophilic organizing pneumonia leading to pseudotumor like appearance [7]. The mechanism responsible for the presence of lung mass in our patient is probably inflammatory eosinophilic parenchymal consolidation, without endobronchial involvement, appearing as pseudotumor, which we had confirmed it with CT guided Lung FNAC. The finding of BAL eosinophilia also suggested this possibility. Although the presence of high attenuation mucus (HAM) has been described as a specific CT feature in ABPA [4], the same was not present in our patient. It is important to note that the appearance of high attenuation mucus is due to the presence of calcium salts and indicates long standing mucus accumulation [7]. In our patient, the quick disappearance of the mass after initiation of treatment indicates an acute event, which dramatically responded to treatment. Our patient had an excellent response to treatment with Prednisolone and Itraconazole, as has been described with previously reported cases.

4. Conclusion

The present case highlights that ABPA should be considered as a differential diagnosis whenever encountering a patient with lung mass and history of asthma.

5. References

1. Greenberger PA. Clinical aspects of allergic bronchopulmonary aspergillosis. *Front Biosci.* 2003; 8:s119-27.
2. Rosenberg M, Patterson R, Mintzer R. Clinical and immunologic criteria for the diagnosis of allergic bronchopulmonary aspergillosis. *Ann Intern Med.*

- 1977; 86:405-14.
3. Patterson R, Greenberger PA, Halwig JM. Allergic bronchopulmonary aspergillosis. Natural history and classification of early disease by serologic and roentgenographic studies. *Arch Intern Med.* 1986; 146:916-8.
4. Agarwal R. Allergic bronchopulmonary aspergillosis. *Chest.* 2009; 135:805-26.
5. Thompson BH, Stanford W, Galvin JR, Kurihara Y. Varied radiologic appearances of pulmonary aspergillosis. *Radiographics.* 1995; 15(6):1273-1284
6. Sánchez-Alarcos JM, Martínez-Cruz R, Ortega L. ABPA mimicking bronchogenic cancer. *Allergy.* 2001; 56:80-1.
7. Agarwal R, Srinivas R, Agarwal AN. Pulmonary masses in allergic bronchopulmonary aspergillosis: mechanistic explanations. *Respir Care.* 2008; 53:1744-8.
8. Coop C, England RW, Quinn JM. Allergic bronchopulmonary aspergillosis masquerading as invasive pulmonary aspergillosis. *Allergy Asthma Proc.* 2004; 25:263-6.
9. Otero González I, Montero Martínez C, Blanco Aparicio M. Pseudotumoral allergic bronchopulmonary aspergillosis. *Arch Bronconeumol.* 2000; 36:351-3.