



Primary pulmonary ewing's sarcoma: Case report

Vipul Kumar¹, Elu Mary Mampilly², Ajit Kumar³

^{1,2,3} Department of Respiratory Medicine, Pt. B.D. Sharma University of Health Sciences, Rohtak, Haryana, India

Abstract

Primary Pulmonary Ewing's sarcoma is an extremely rare neuroectodermal tumour. Ewing's sarcoma family is a group of aggressive tumours, mostly arising from bone. Extraskkeletal Ewing's sarcoma involving the lung is extremely rare, with only few cases reported till date. We report a case of a 17-year old female who was diagnosed of Primary pulmonary Ewing's sarcoma who presented with breast swelling, chest pain, cough and breathlessness associated with right lung mass on chest radiography. Patient was started on chemoradiation and has symptomatically improved. Patient is at present under evaluation of surgical intervention.

Keywords: Primary pulmonary Ewing's sarcoma, neuroectodermal tumour

1. Introduction

Ewing's sarcoma family is a group of aggressive tumors, in most cases, originating from bone. First described by American pathologist James Ewing¹ in 1921, this group of tumors comprises Ewing sarcoma (osseous and extraosseous), primitive neuroectodermal tumor (PNET) of the bone and soft tissues, Askin tumor (PNET of the thoracopulmonary region), and other less common tumors (eg. ectomesenchymoma, peripheral medulloepithelioma). Ewing sarcoma usually manifests during the second decade of life with male predominance. Extraskkeletal Ewing's sarcoma of the lung is very rare, and only a few cases have been reported.² Histologically, Ewing's sarcoma family of tumours (ESFT) are malignant, small, round-cell tumors. We present the case of a 17-year old female who was diagnosed of Primary pulmonary Ewing's sarcoma in the Department of Respiratory Medicine, Pt. B.D.Sharma PGIMS, Rohtak, Haryana.

2. Case Report

A 17 year old female presented to our clinic with painful swelling in the right breast, dry cough and breathlessness since two months. Medical and Family history was unremarkable. Vitals were stable on examination. The swelling was hard, tender and fixed to the chest wall. There was no evidence of lymphadenopathy. Breath sounds were decreased on the right side.

Chest radiograph showed large homogenous opacity in right lung with right hydropneumothorax. (Fig.1)

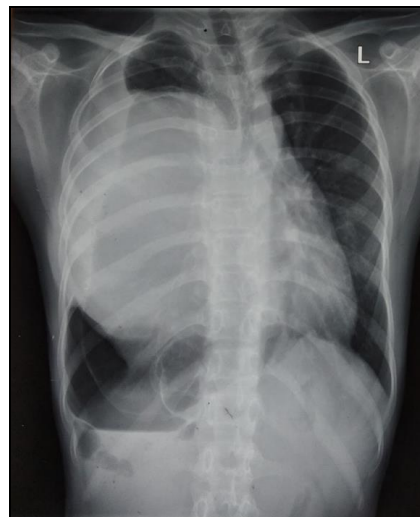


Fig 1: Postero-anterior chest radiograph demonstrating large homogenous opacity in right lung with right hydropneumothorax.

USG thorax revealed that the mass lesion is in the thoracic cavity involving the intercostal muscles and deeper surface of pectoralis muscle. Both the breasts were normal in USG. CECT Thorax revealed large ill-defined heterogeneously enhancing lesion in the right hemi thorax infiltrating right chest wall and anterior aspect of right 3rd rib with minimal right sided pleural effusion. Thoracentesis was done. Pleural fluid was haemorrhagic and suggestive of exudative effusion. CT guided FNAC was done. (Fig.2)

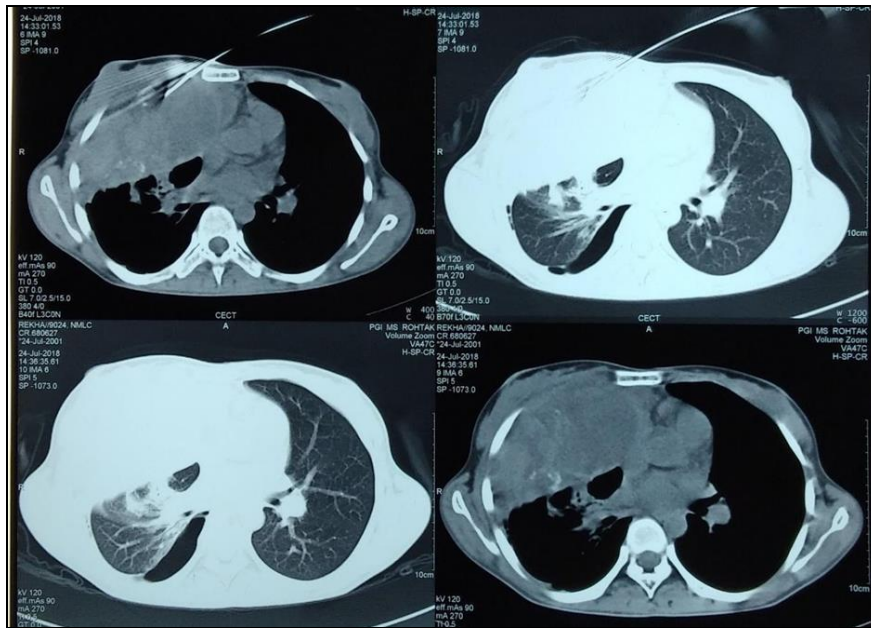


Fig 2: Contrast enhanced CT scan of the thorax showing large ill-defined heterogeneously enhancing lesion in the right hemithorax infiltrating right chest wall and anterior aspect of right 3rd rib with minimal right sided pleural effusion.

CT guided FNAC showed large, undifferentiated small round cells present in groups, clusters and pseudorosettes with pleomorphic nuclei. Mitotic figures were also seen. Cytological features were suggestive of Malignant Small Cell tumour favouring Ewing's sarcoma/PNET. (Fig.3)

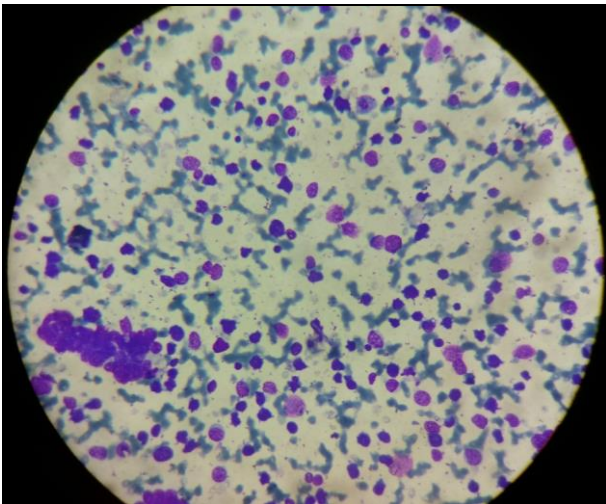


Fig 3: Showing large, undifferentiated small round cells present in groups, clusters and pseudorosettes with pleomorphic nuclei. Cytological features were suggestive of Malignant Small Cell tumour favouring Ewing's sarcoma/PNET.

The imaging and cytological features were suggestive of pulmonary Ewing's sarcoma. Patient was started on chemoradiation and has symptomatically improved. Patient is at present under evaluation of surgical intervention.

3. Discussion

Ewing's sarcoma family of tumours (ESFT) incorporates both the well-recognised bone sarcoma primary tumours and extraskeletal tumours. Primitive neuroectodermal tumours (PNET) and extraskeletal Ewing's sarcoma can be considered as the same entity as have a similar neural phenotype. The histologic differential diagnoses comprised other small, round cell malignancies, including

neuroblastoma, malignant lymphoma, and embryonal rhabdomyosarcoma. Immunohistochemical and histochemical staining positive for glycogen (PAS, 80%), neuron-specific enolase (60%), S-100 protein (50%) and MIC-2 marker (90%), as well as negative findings for leukocyte common antigen, epithelial membrane antigen, cytokeratin, desmin, vimentin, myoglobin and glial fibrillary acidic protein all point towards a diagnosis of Ewing sarcoma [4].

Ewing sarcoma usually affects patients in the second decade of life and has male predominance. Our case is a 17 year old female almost at the end of second decade of life [5]. Considering the rarity of primary pulmonary PNETs, it is necessary to conduct detailed examination by clinical and radiological means in order to rule out metastatic tumour from an extrapulmonary primary site. The clinical picture is not specific. Most patients (90%) present with a painful chest wall mass. Fever and malaise are commonly associated systemic manifestations [6]. Characterization of pulmonary Ewing sarcoma has been limited. However in CT, primary pulmonary Ewing sarcoma mostly presents as a circumscribed solitary mass with heterogeneous appearance. Sometimes, intralesional calcifications or an ipsilateral pleural effusion may be seen. Less frequently, a mass may demonstrate evidence of invasion of adjacent structures.⁷ The main radiological finding in our case was a large heterogeneous soft tissue lung mass on the right side. Possibility of a primary malignancy from another site was ruled out by a full body scan. Our case matched the clinical, radiological and cytological features of a primary pulmonary Ewing's sarcoma.

Globally, less than 20 cases of Primary pulmonary Ewing's sarcoma have been reported so far. Management of primary pulmonary EES/PNET usually needs aggressive multimodality treatment with upfront surgery followed by chemotherapy with or without radiotherapy [5]. It can be concluded from the cases on record now that ESFT of the lung is an aggressive malignant tumour. The most significant prognostic factor in ESFT to be considered is whether the disease has spread. At diagnosis of Ewing's

sarcoma, approximately 25% of patients have metastatic spread. Factors such as tumour size, however, are not surmised to show prognostic value^[8].

4. Conclusion

Primary Ewing's sarcoma of the lung should be considered in the differential diagnosis when a young patient is presented with large lung mass without evidence of primary extrathoracic disease.

5. References

1. Renard C, Ranchère-Vince D. Ewing/PNET sarcoma family of tumors: towards a new paradigm? *Ann Pathol.* 2015; 35:86-97.
2. Asker S, Sayir F, Bulut G, Sunnetcioglu A, Ekin S, Yavuz A. Primitive neuroectodermal tumor/Ewing sarcoma presenting with pulmonary nodular lesions. *Case Rep Oncol Med.* 2015; 2015:957239.
3. Bernstein M, Kovar H, Paulussen M, Randall RL, Schuck A, Teot LA *et al.* Ewing's sarcoma family of tumors: current management. *Oncologist.* 2006; 11:503-519.
4. Christie DR, Bilous AM, Carr PJ. Diagnostic difficulties in extraosseous Ewing's sarcoma: a proposal for diagnostic criteria. *Australas Radiol.* 1997; 41:22-8.
5. Takahashi D, Nagayama J, Nagatoshi Y, Inagaki J, Nishiyama K, Yokoyama R *et al.* Primary Ewing's sarcoma family tumors of the lung a case report and review of the literature. *Jpn J Clin Oncol.* 2007; 37:874-877.
6. Dong M, Liu J, Song Z, Li X, Shi T, Wang D *et al.* Primary multiple pulmonary primitive neuroectodermal tumor: case report and literature review. *Medicine (Baltimore).* 2015; 94:e1136.
7. Shet N, Stanescu L, Deutsch G. Primary extraosseous Ewing sarcoma of the lung: case report and literature review. *Radiol Case Rep.* 2013; 8:832.
8. Ahmad R, Mayol BR, Davis M, Rougraff BT. Extraskelatal Ewing's sarcoma. *Cancer.* 1999; 85:725-731.